

COMPARISON OF FGF -8, FGF -10, FGF- RECEPTOR 2, ANDROGEN RECEPTOR, ESTROGEN RECEPTOR-A AND SS IN HEALTHY AND HYPOSPADIAC CHILDREN

Emaratpardaz N¹, Turkyilmaz Z¹, Karabulut R^{1*}, Dayanir D², Kaya C¹, Sert AAE², Arkan G¹, Ucaner FA¹, Kapisiz A¹, Eryilmaz S¹, Atan A³, Sonmez K¹

*Corresponding Author: Prof. Ramazan Karabulut, MD, Gazi University Faculty of Medicine, Department of Pediatric Surgery, Besevler, 06550, Ankara-Turkey. Tel: +90 312 2026210; Fax: +90 312 2230528. E-mail: karabulutr@yahoo.com, ramazank@gazi.edu.tr

ABSTRACT

In this study, we aimed to investigate the levels of Fibroblast Growth Factor-8 (FGF-8), FGF-10, FGF-Receptor-2 (FGFR-2), Androgen receptor (AR), Estrogen receptor alpha and beta (ER- α and ER- β) in the foreskins of children with and without hypospadias.

Methods: Samples from the foreskins of 20 children with hypospadias and 20 skin samples from children without hypospadias between the ages of 14 months and 12 years were taken during circumcision or hypospadias correction surgery for immunohistochemical (IHC) examination of these markers. In IHC examination, it was shown that ER- α , ER- β and AR receptors were more involved in the foreskin of children with hypospadias than in the foreskin of without hypospadias children, and FGF-8, FGF-10 and FGFR-2 were lower ($p < 0.05$). ER and AR uptake were higher in hypospadias tissue samples and FGF-8, FGF-10, and FGFR-2 uptakes were lower compared to without hypospadias children's tissue samples, and these factors were supported by affecting each other in the development of hypospadias. The limited number of studies on this subject in the literature and the contradictory results of the findings indicate that more research should be done on this subject in the future.

Keywords: hypospadias, FGF receptors, androgen receptor, estrogen receptors, etiology

INTRODUCTION

Hypospadias is a genital anomaly characterized by the location of the external urethral meatus on the ventral side of the penis, in the scrotum, or perineum, affecting approximately one in every 200-300 boys. It is considered to be the most common congenital anomaly after undescended testis in boys [1,2]. There are many classifications for hypospadias. According to Duckett's classification, which is widely used by pediatric surgeons, hypospadias is classified as proximal and distal. In distal hypospadias, detected in approximately 70% of cases, the urethral meatus may be located in the glandular area, coronal area, and distal shaft of the penis. In proximal hypospadias, which is detected in approximately 30% of cases, the urethral meatus may be located in the middle penile region, proximal penile shaft, penoscrotal or perineal regions [3]. Investigations of genetic, endocrine and environmental factors in the etiology of hypospadias are still ongoing. Studies on the effects of environmental and endocrine factors have shown that factors such as small gestational age (SGA), placental insufficiency, maternal hypertension, preeclampsia, antiepileptic drugs use, multiple pregnancy, gestational diabetes, maternal obesity often play an effective role in the etiology of hypospadias [4]. Although many genetic syndromes include hypospadias, hypospadias due to genetic causes accounts for less than 10% of all cases. The risk of developing hypospadias in a brother of a patient with hypospadias is more than 10% [5]. Although it is known that the frequency of proximal hypospadias increases with some syndromes, there is usually sporadic occurrence for distal hypospadias. It has been shown that the expression of some genes and defects in androgen and estrogen production in the genital tubercle and urethral plate may also be effective in the etiology of hypospadias

¹ Gazi University Faculty of Medicine, Departments of Pediatric Surgery, Ankara, Turkey

² Gazi University Faculty of Medicine, Departments of Histology and Embryology Ankara, Turkey

³ Gazi University Faculty of Medicine, Departments of Urology, Ankara, Turkey

(*SHH, ER1, ER2, GL1, GL2, GL3, ATF3, FGF-8, FGFR-2, VAMP7, WT1, BMP7, WNT5A, DGKK* etc.) [5,6]. It is known that Fibroblast Growth Factors (FGF) have a very important contribution to the fusion of the urethral folds and the development of the genital tubercle, and play a role in wound healing and tissue regeneration [7]. Additionally, androgen receptors (AR) are also found to play an important role in male sexual differentiation with the effect of gonadal androgens. Decreased expression of AR has also been reported to have consequences such as infertility, testicular atrophy, micropenis, hypospadias, and decreased sperm production. The decreased response to human chorionic gonadotropin (hCG) stimulation in children with hypospadias points to the importance of this receptor in the etiology of hypospadias [8]. Studies have found that there were significant differences in terms of estrogen receptors (ERs) in the foreskins of children with or without hypospadias, and these data showed that this difference may play a role in the etiology of hypospadias [9,10,11]. As well as the surgical treatment of hypospadias, investigation into ways of preventing the disease has gained importance due to its increasing prevalence [12]. Prevention of hypospadias or medical treatment research is important to prevent psychosexual problems of the patients due to possible chordee, fistula and poor cosmetic results that may occur in adulthood after surgical treatment applied in childhood.

In this study, levels of fibroblast growth factor 8 (FGF-8), FGF-10, FGF Receptor-2 (FGFR-2), AR, ER- α and ER- β were compared in order to discover the etiology of hypospadias in foreskin tissues of children with and without hypospadias.

MATERIAL AND METHODS

Approval from the Gazi University Ethical Committee was obtained before the study began (07/03/2022-191). The study includes the children with hypospadias and the ones without who came to our clinic for circumcision. The children who underwent circumcision were the control group. After giving detailed information, written informed consent was obtained from their legal guardians (parents). Children who had previous hypospadias surgery, received hormone therapy, had accompanying urological anomalies such as undescended testis, had endocrine disorders and syndromes were excluded from the study. Between June 2022 and September 2022, 20 children with hypospadias and 20 children who applied just for circumcision were included. All children met the criteria. During circumcision and hypospadias correction surgery, the foreskin tissues about 1x1 cm from healthy and children with hypospadias were taken for histomorphological and immunohis-

tochemical (IHC) studies. Levels of AR, ER- α and ER- β , FGF-8, FGF-10, FGFR-2 were evaluated in these tissues.

Using Microsoft Office Excel Professional Plus 2016 (Microsoft Corporation, Redmond, WA, USA), statistical analysis was carried out. To compare the quantitative data between two groups that did not exhibit a normal distribution, the Mann-Whitney U test was employed.

Histomorphological Evaluation

Tissue samples were fixed in 10% neutral formaldehyde for 48 h. After washing the fixed tissues in running water for 24 hours, they were kept in 70% ethyl alcohol, 80% ethyl alcohol, 96% ethyl alcohol, Acetone I, Acetone II, Acetone III and Acetone IV, for 20 minutes each, respectively. Tissues extracted from acetone were kept in Xylene I and Xylene II for 30 minutes each. Before the tissues were embedded, they were kept in molten Paraffin I and Paraffin II for 1 hour in an oven at 60°C and embedded in paraffin blocks. Sections of 6 μ m thickness obtained from the blocks were kept in xylol for 2 times for 15 minutes. Samples extracted from xylol were kept in ethyl alcohol solutions at 100%, 96%, 90%, 80%, 70% and 50% concentrations, respectively, for 10 minutes, then rehydrated by soaking them in distilled water for 5 minutes, twice. Sections obtained from the blocks were then stained with Hematoxylin Eosin (H&E) for histological evaluation. The samples, which were dehydrated by passing through the alcohol series, were kept in xylol and covered with a lamella using entellan. All specimens were evaluated histopathologically by taking photographs with the Leica Q Vin 3 program with the help of Leica DM4000 (Germany) computer aided imaging system. These evaluations were examined separately by 2 instructors working in the Histology and Embryology Department.

Immunohistochemical evaluation

Tissue samples were processed similar to the histomorphological stage. Afterwards, the tissues were lined up on the immunohistochemistry bar in a humid environment and were scratched with PAP-Pen and washed 3 times with PBS (Phosphate Buffer Saline, pH: 7.4) for 3 minutes. Samples were treated with serum blocking solution for 10 minutes to prevent non-specific binding, AR Ab-1 (Cat. No. MS-443-PO, Thermo Fisher Scientific, Cheshire, UK), ER- α (Cat. No. RM-9101-SO), Thermo Fisher Scientific, Cheshire, UK), ER- β (Cat. No. orb448242, Biorbyt Ltd., Cambridge, UK), FGFR-2 (Cat. No. STJ91850, St Johns Laboratory Ltd., London, UK), FGF-8 (Cat. No. PA1216, Boster Biological Technology, Pleasanton, CA, USA), FGF-10 (Cat. No. E-AB-65862, Elabscience Biotechnology Inc., Houston, TX, USA) primary anti-

bodies were incubated at +4°C for 1 night. After incubation, a 3% hydrogen peroxide solution was applied to the samples washed with PBS for 15 minutes to inhibit endogenous peroxidase activity. After washing the samples with PBS, a secondary antibody with biotin was applied. Again, the samples were washed 3 times with PBS for 3 minutes, and chromogen containing diaminobenzidine (DAB) substrate was applied and left until a visible immune reaction occurred. Mayer's Hematoxylin was used as background dye for the samples washed with PBS. The samples, which were dehydrated by passing through the alcohol series, were kept in xylol and covered with a lamella using entellan. All samples were evaluated with the help of the Leica DM4000 (Germany) computer aided imaging system. Photographs were taken using the Leica Q Vin 3 program. Uptake of AR, ER- α and β in cell counts provided in 10 independent fields selected for each slide and were evaluated with the scoring system specified by Qiao et al. [9] (Table 1).

The evaluation of FGF-8, FGF-10 and FGFR-2 was done as follows, taking the study of Haid et al. as an example [7];

Epidermis assessment

- Pattern 1: Limited to basal involvement
- Pattern 2: Less than 50% of keratinocytes are involved
- Pattern 3: Involvement of more than 50% of keratinocytes

Table 1. Quantitative scoring system of stratified squamous epithelium by immunohistochemistry for AR, ER- α and ER- β .

Score	Grade
0	No involvement
+	Involvement in basal keratinocytes
++	Involvement limited to the lower 1/3 of the epidermis
+++	Involvement limited to the lower 2/3 of the epidermis
++++	Involvement in all epidermis layers

Dermis evaluation:

- Pattern A: No positive cells
- Pattern B: diffuse involvement in less than 50% of all visible dermal cells
- Pattern C: Clustered positive cells more than 50% of all visible dermal cells.

RESULTS

The study was carried out with a total of 40 children. The children's ages ranged from 14 months to 12 years with a mean age of 65.92 ± 33.20 months. The mean age in the control group was 59.40 ± 31.80 months (12-108 months) and the mean age in the hypospadias group was 72.45 ± 34.09 (14-132 months). Of the patients with hypospadias, 2 had coronal, 11 had subcoronal and 7 had mid-penile hypospadias. In the H&E stained sections of the preputial tissues obtained from both groups, the epidermis was observed to be consistent with the features of the stratified squamous epithelium. There was no significant histomorphological differences between two groups ($p > 0.05$).

IHC uptake of AR, ER- α , ER- β markers was evaluated with the quantitative scoring system of stratified squamous epithelium [9]. While the score was (+) in 18 patients in the AR control group, the score was (+++) in 15 patients with hypospadias and (++) in 5 patients. Similarly, ER- α and ER- β markers were detected in a larger area in the epidermis in the hypospadias group (Table 2), (Fig. 1, 2 and 3). When the AR and ER receptors were scored, it was shown that the foreskin of children with hypospadias contained statistically higher AR and ERs than the foreskin of children without hypospadias (Table 4) ($p < 0.05$).

The levels of FGFR-2, FGF-8, FGF-10 in epidermis and dermis were quantitatively evaluated. The involvement pattern was classified as 1, 2, 3 for epidermis and classified as A, B, C for dermis. When the epidermis area was examined, Pattern 3 involvement was observed

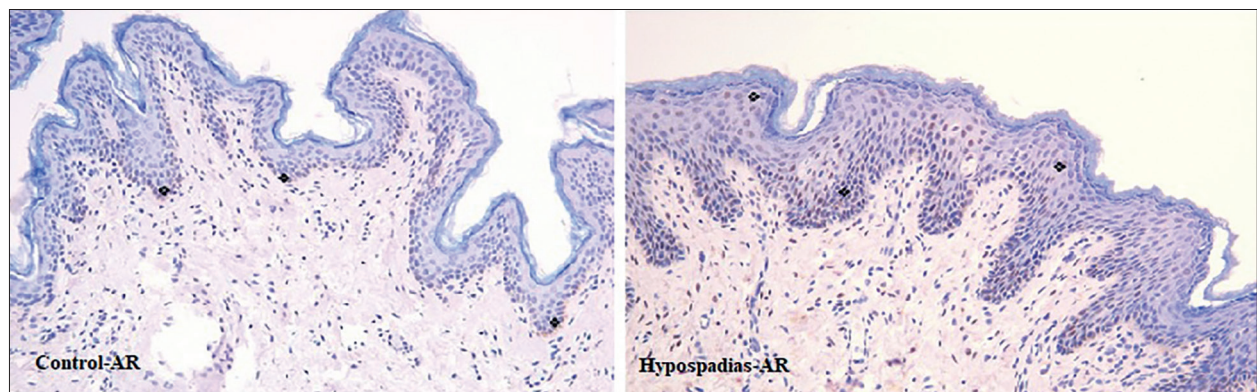


Figure 1. AR uptake was observed in basal keratinocytes in control group. AR involvement was limited to the lower 2/3 of the epidermis in the hypospadias group (IHC Staining, 200 X).

Table 2. Quantitative scoring results of stratified squamous epithelium for AR and ERs (n=20).

Score	AR		Estrogen Receptor- α		Estrogen Receptor- β	
	Control	Hypospadias	Control	Hypospadias	Control	Hypospadias
0	1	-	2	-	-	-
+	18	-	17	-	18	-
++	1	5	1	4	2	3
+++	-	15	-	16	-	17
++++	-	-	-	-	-	-

Table 3. Epidermis and dermis involvement of FGFR-2, FGF-8, FGF-10(n=20).

	Pattern	FGFR-2		FGF-8		FGF-10	
		Control	Hypospadias	Control	Hypospadias	Control	Hypospadias
Epidermis	1	-	-	-	16	-	17
	2	4	-	5	4	2	3
	3	16	5	15	-	18	-
Dermis	A	-	1	-	3	-	2
	B	3	19	14	17	3	18
	C	17	-	6	-	17	-

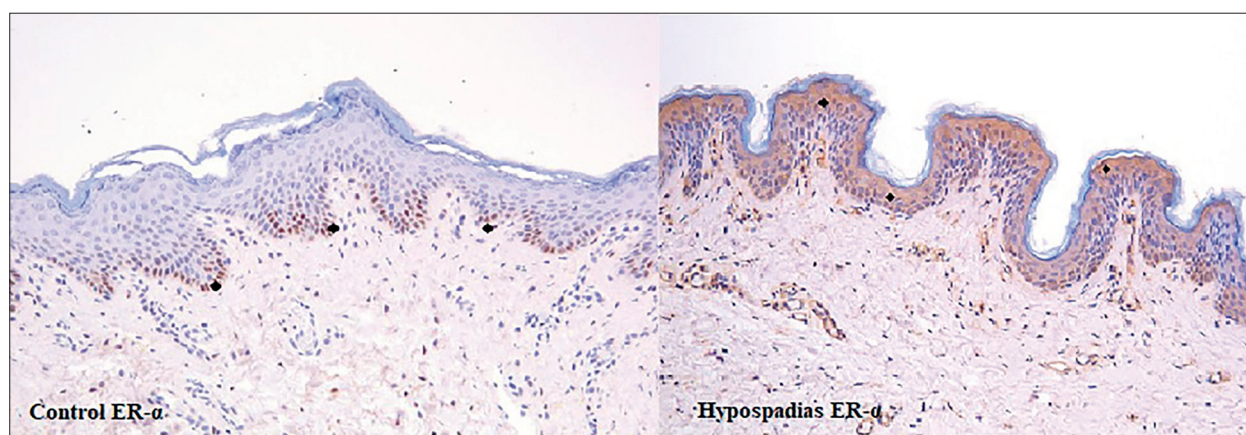


Figure 2. ER- α uptake was observed in basal keratinocytes in control group. ER- α involvement was limited to the lower 2/3 of the epidermis in the hypospadias group (IHC Staining, 200 X).

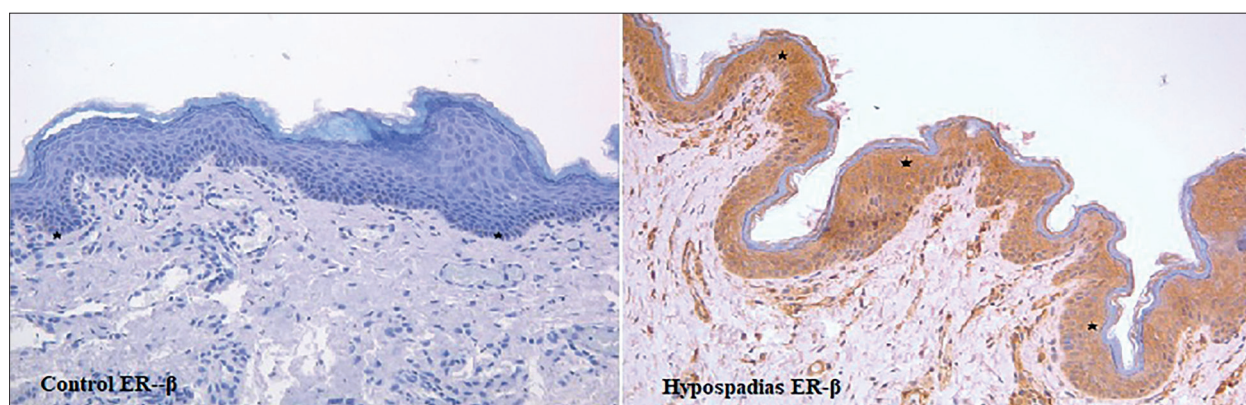


Figure 3. ER- β uptake was observed in basal keratinocytes in control group. ER- β involvement was limited to the lower 2/3 of the epidermis in the hypospadias group (IHC Staining, 200 X).

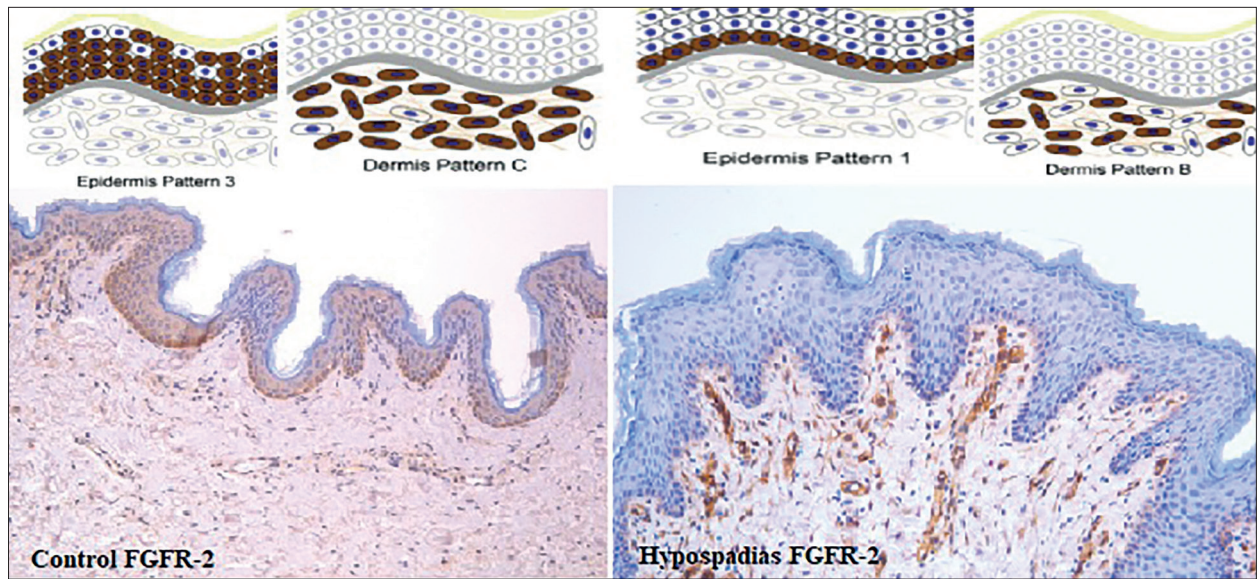


Figure 4. In the control group, FGFR-2 uptake was observed in more than 50% of Keratinocytes (Epidermis Pattern 3) and clustered positive cells in more than 50% of all visible dermal cells (Dermis Pattern C). Limited to basal involvement in hypospadias group (Epidermis Pattern 1) and involvement of less than 50% of dermal cells (Dermis Pattern B) (IHC Staining, 200 X).

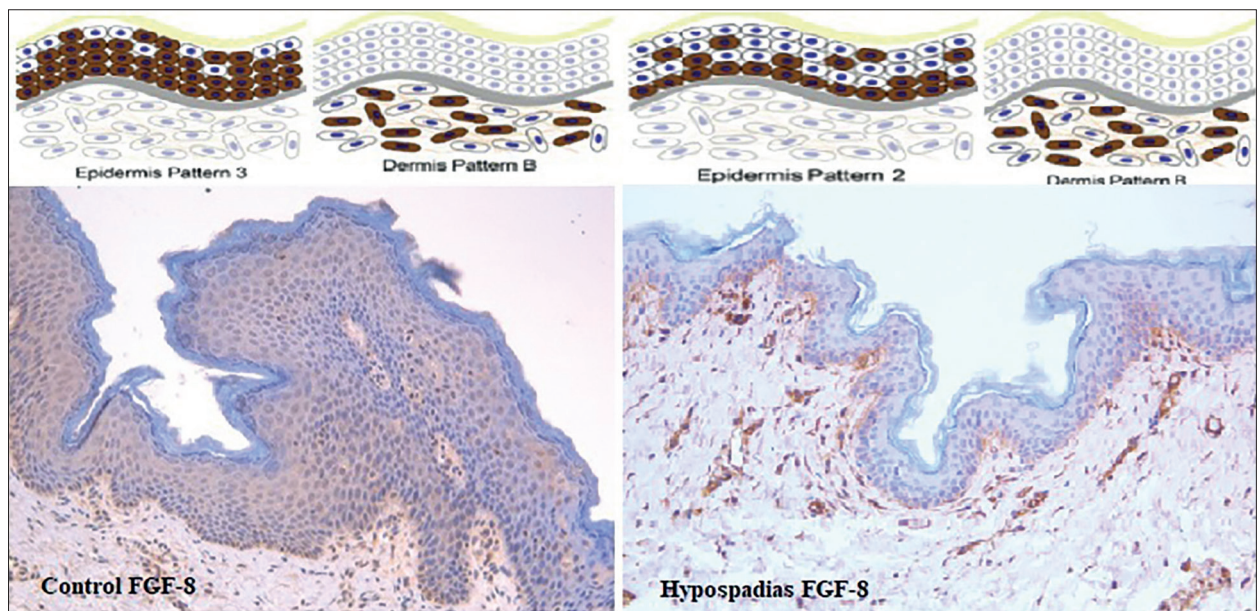


Figure 5. In the control Group, more than 50% of keratinocytes were involved (Epidermis Pattern 3) and less than 50% of dermal cells are involved (Dermis Pattern B) for FGF-8. In the hypospadias group, it was limited to basal involvement (Epidermis Pattern 1) and involvement of less than 50% of dermal cells (Dermis Pattern B) (IHC Staining, 200 X).

predominantly in control patients, while Pattern 1 involvement was observed in patients with hypospadias. When the dermis areas were examined, it was observed that 17 of the patients in the control group of FGFR-2 had Pattern C, 3 had Pattern B, 19 patients with hypospadias had Pattern B and 1 had Pattern A involvement (Fig. 4). If FGF-8, 6 Pattern C and 14 Pattern B uptake

were detected in control patients, while 17 Pattern B and 3 Pattern A uptake were detected in hypospadias patients (Fig.5). It was Pattern C in 17 of the FGF-10 control patients, Pattern B in 3 of the patients with hypospadias, it was observed as Pattern B in 18 of the patients with hypospadias and as Pattern A in 2 of the patients with hypospadias (Fig.6), (Table 3).

Table 4. Mean \pm SD values of the markers in the groups for IHC evaluation. * $P < 0.001$, ** $P < 0.05$.

	Control	Hypospadias
Androgen Receptor	$2 \pm 0,32$	$3,75 \pm 0,44^*$
Estrogen Receptor- α	$1,95 \pm 0,39$	$3,80 \pm 0,41^*$
Estrogen Receptor - β	$2,10 \pm 0,30$	$3,85 \pm 0,36^*$
FGFR-2 Epidermis	$3,80 \pm 0,41$	$2 \pm 0,32^*$
FGFR-2 Dermis	$2,85 \pm 0,36$	$1,95 \pm 0,22^*$
FGF-8 Epidermis	$3,75 \pm 0,44$	$2,15 \pm 0,48^*$
FGF-8 Dermis	$2,30 \pm 0,47$	$1,85 \pm 0,36^{**}$
FGF-10 Epidermis	$3,90 \pm 0,30$	$2,15 \pm 0,36^*$
FGF-10 Dermis	$2,85 \pm 0,36$	$1,90 \pm 0,30^*$

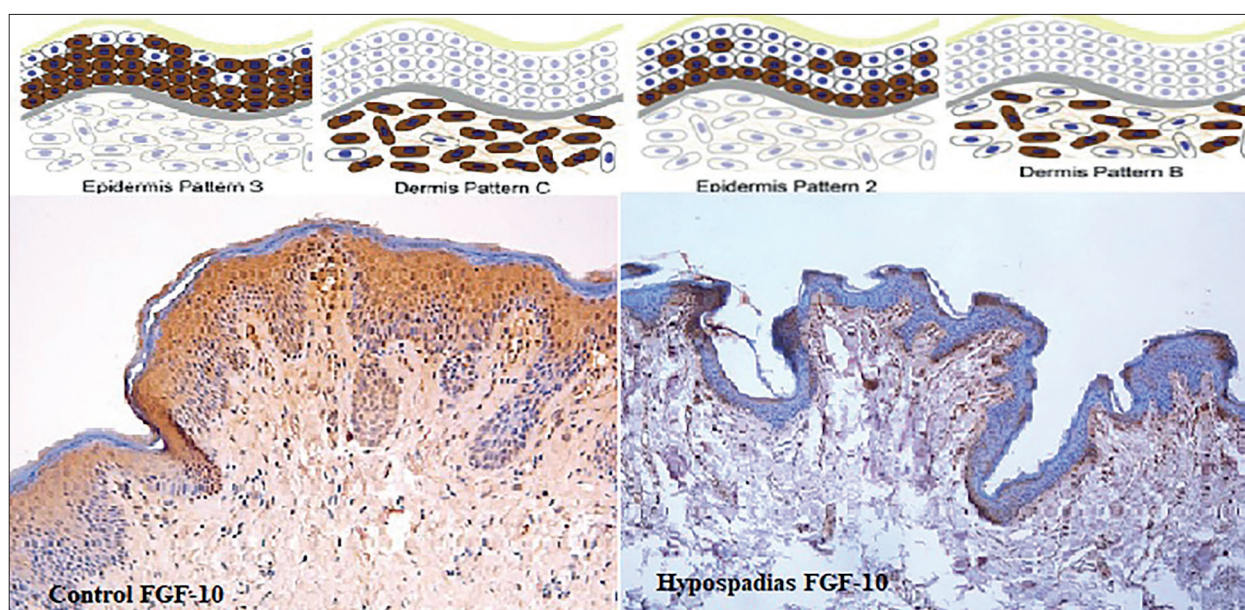


Figure 6. More than 50% involvement of keratinocytes (Epidermis Pattern 3) and clustered positive cells more than 50% of all visible dermal cells (Dermis Pattern C) for FGF-10 in the control group. In the hypospadias group, less than 50% of keratinocytes were involved (Epidermis Pattern 2) and involvement of less than 50% of dermal cells (Dermis Pattern B) (IHC Staining, 200 X).

There was a higher rate of uptake in both epidermis and dermis areas for FGFR-2, FGF-8 and FGF-10 in the control group. There was a statistically significant difference between two groups ($p < 0.05$) (Table 4).

DISCUSSION

Hypospadias is considered the most common congenital anomaly after undescended testis in males. It is thought that there are multifactorial causes in the etiology of hypospadias, and there are many studies in the literature on molecular, genetic and environmental factors for etiology [1,2,13,14]. Hypospadias can arise as a result of embryological defects that affect the development of the urethra, which is connected to mesothelial-epithelial interaction, as well as the preputium and penile skin, which

are of ectodermal origin [7]. It has been demonstrated that androgens enable the development and differentiation of the mouse and human penis, and that hypospadias results from a lack of androgens. Pregnant women who receive diethylstilbestrol (DES), a synthetic estrogen, have an increased risk of developing hypospadias [15]. Preoperative androgen stimulation has demonstrated to enhance penile size but not the risk of postoperative problems, and the degree of hypospadias does not alter the lengthening of the penis in response to androgen stimulation [16]. AR mutations have also been found to be associated with hypospadias [17]. Low serum testosterone levels, decrease in androgen-dependent pathways in the cell nucleus and increase in cytoplasmic estrogen-dependent pathways may cause hypospadias and undescended testis [14]. Intrauterine factors, such as abnormal androgen production by

the fetal testes, partial androgen insensitivity in the target tissues of the developing genitalia, and early atrophy of Leydig cells and premature cessation of androgen stimulation, have been implicated. In hypospadias, especially in its severe forms, abnormalities have been reported in the enzyme 5- α -reductase type 2, which catalyzes the conversion of testosterone to dihydrotestosterone [10]. For both the male and female sexes, it is well established that ERs and estrogen are essential for healthy genital development. The estrogen derivative diethylstilbestrol and the anti-estrogen letrozole (an aromatase inhibitor) have been administered to people and animals, and studies have shown that hypospadias develop as a result of an imbalance in estrogen levels [15].

Contrary to what Khanna et al.'s investigation found in the foreskin of children with and without hypospadias circumcision samples showed enhanced ER expression and decreased AR expression [10]. According to our research, children with hypospadias have more ER and AR receptors in their foreskins. Again, in the preliminary study of Pichler et al. on this subject, it was shown that AR mRNA expression and IHC AR protein level and AR protein staining in nuclear staining increased in the foreskin of children with hypospadias, and this increase was correlated with the degree of hypospadias. They stated that the elevation of AR mRNA and AR protein in preputium samples of boys with hypospadias is an indirect indicator of decreased AR DNA binding capacity. Therefore, they pointed to a signal defect indicating more deficient polypeptide encoding as a possible cause of hypospadias. They stated that more research on the notion should be conducted using structural analysis of AR to ascertain whether the degree of AR signaling malfunction and the severity of hypospadias are indicated by differences in the expression of AR mRNA and AR protein [8]. Although expression studies were not performed in our study, AR levels were found to be high in the tissue, and results supporting this theory were obtained. In the study of Celayir et al., in which the skin obtained from 33 children with hypospadias was examined, ER was found to be positive in 29 (87.8%) tissues and AR in 12 (36.4%) tissues. The progesterone receptor was found to be negative (0%) in all specimens [18].

According to Cunha et al., estrogens are essential for the development of the penile and clitoral regions in hyenas, as well as for determining the location of the urethral orifice, providing flexibility to the urethral meatus, and facilitating epithelial fusion events that are required for the correct formation of the distal urethra, urogenital sinus, and foreskin. Significant tissue expression of androgen and estrogen receptors is linked to the effects of prenatal androgens, anti-androgens, and decreased production of estrogen, indicating that estrogen, like androgen, plays an

active role in prenatal penile development [19]. Celayir et al. described the predominant expression of ERs in the penile tissue of children with hypospadias as a postnatal reflection of impaired ER and AR interaction during the intrauterine development of external genitalia and interpreted that impaired AR and ER interaction may play a role in the development of hypospadias and external genital organs [18]. Similarly, Qiao et al. investigated the effects of estrogen in hypospadias and circumcision tissue. They found the mRNA expression of ER- α and β (dominant character in foreskin without hypospadias) significantly lower in hypospadiac skin compared to the control group [9]. In addition, ER- β was IHC stained weakly in preputial tissue, but prominently in skin without hypospadias. ER- α , on the other hand, was weakly stained in without hypospadias and mildly hypospadiac skin but could not be detected in severe hypospadias [9,10]. As a result, they stated that there is a tendency towards lower ER expression levels in severe hypospadias compared to mild hypospadias, and changes in ER levels play a role in the development of normal and abnormal foreskin [9]. In our study, both ER and AR were found to be increased in hypospadiac skin. These results are evidence that both estrogen and androgens play a role in the development of the genital system and the formation of hypospadias. The increased ER and AR receptor scoring in patients with hypospadias can be shown as the continuation of the above-mentioned and beginning of the intrauterine ER and AR balance, and perhaps the body's attempt to balance this imbalance.

The union of the urethral folds and the formation of the genital tubercle depend on FGFs, especially FGF-8, FGF-10, and FGFR-2. The development of severe hypospadias in mutant mice has also been demonstrated. Since members of the FGF family have a role in the interaction between mesenchyme and urothelium, the development of genital tissues, it has been demonstrated that abnormalities increase the risk of hypospadias [20]. Single-base mutations in FGF-8, FGF-10, and FGFR-2 are associated with hypospadias in humans, and it has been shown to increase the risk (3-4 times) of hypospadias compared to the control group [7]. However, studies on the concentration or receptor density of these factors in the foreskin or penile tissue are limited. In the pioneering study of Haid et al. investigating the density of FGF family components in the hypospadias foreskin, no difference was found in the expression levels of FGF-8, FGF-10, FGFR-2 mRNA in the foreskin of 32 hypospadias patients compared to the normal foreskin, but a significant difference was observed in the IHC staining distribution [7]. Compared to the control group, IHC staining of these markers were found to be higher (2/3) in a higher pattern, especially in those with hypospadias in the epidermis, while these markers were

more pronounced in those with proximal hypospadias than in those with distal hypospadias ($p < 0.05$). While these HGFs were stained in a higher pattern in the dermis than in the control group (B/C), they showed a similar staining pattern among hypospadias types. Haid et al. emphasized that they showed that FGFs play an active role in the formation of hypospadias by associating their results with hypospadias caused by mutations of FGF-8, FGF-10 and FGFR-2 in mouse models. These findings offer compelling evidence in favor of the theory that mutations in FGF components associated with the initial phases of genital development could impact tissues produced from human ectodermal tissue. This implies that people with hypospadias may have significantly changed dartos fascia microanatomy as a result of FGFs acting on mesenchymal tissues. The induction of overlaying epithelial differentiation by mesenchymal FGF production is a well-established phenomenon. Cross-epithelial-mesenchymal boundaries have been shown to exhibit both directionally and reciprocally active FGF signaling. They did not make any specific comments about the development of hypospadias, saying that poor wound healing and the frequency of complications are mostly reflected in the changes in this FGF family in patients with severe hypospadias [7]. In our study, which is the second study on this subject, no mRNA expression study was performed, but lower scores were obtained in the hypospadias group in the IHC studies of FGF-8, FGF-10, and FGFR-2 in both epidermis and dermis.

Expression of FGF-8 and FGF-10, especially FGFR-2, is positively regulated by AR receptors based on androgen response element sequences in human hypospadias foreskin tissue. However, AR expression works independently of FGFs and without feedback [21, 22]. The changes in these FGF values in our study and Haid's study may be due to the disruption of the balance between FGFs and AR, which was described above [7]. Despite the low FGF in our study, the low AR levels may be due to the lack of feedback.

While endodermal FGFR-2 deletion causes mild hypospadias and defective urethral epithelium, ectodermal FGFR-2 deletion causes severe hypospadias and ventral prepuce loss [23]. FGF-8, FGF-10, and FGFR-2 are closely linked through Sonic Hedgehog regulation, particularly with the formation of the limbs and genital tubercle at an early androgen-independent stage of embryonic development. Mesenchymal FGF signaling affects the ectodermal and endodermal epithelium, causing overgrowth of the genital tubercle. Although it has been shown in the literature in mouse models that FGF-8, FGF-10 and FGFR-2 affect the development of tissues of ectodermal origin, such as penile skin and foreskin, this finding has not yet been confirmed in human tissue [23]. Whether it is the

study of Haid et al. or our own study, although there are different results due to the limitations of the studies on this subject, penile tissue FGF-8, FGF-10 and FGFR-2 uptake and scores were different compared to the control group in these studies, and the FGF family also had genital development in humans, and evidence that it is associated with hypospadias [7].

The limitations of this study are the limited number of cases due budget limitations, the inability to measure blood estrogen and androgen levels, and the inability to express mRNA. As in other hypospadias studies, the results reflect a small group because they sample a single ethnic population or race. The strength of this study is that AR, ER, and FGF-8, FGF-10, and FGFR-2 are the only studies that looked at the same time.

CONCLUSIONS

IHC studies on the foreskin of children with hypospadias and without hypospadias revealed that ER and AR uptake were higher in hypospadias tissue samples, also that FGF-8, FGF-10, and FGFR-2 uptakes were lower compared to the children's tissue samples who did not have hypospadias. These factors were supported by affecting each other in the development of hypospadias. There are not many studies on this topic in the literature, and the conflicting results for some of the analyzed criteria suggest that further study on this topic needs to be done in the future.

Funding

This study was sponsored by the Scientific Research Foundation of Gazi University (9/2022-7828).

Authors' Contribution

NE, ZT, RK, AA and KS **performed** to study conception and design. NE, GA and FAU **performed data** acquisition. DD, AAMS, NE and RK **performed analysis** and data interpretation. ZT, RK and KS **read** and re-written the article. KS and AA **were** involved in revision of the article and mentorship throughout. All authors read and approved the final version of the manuscript

Ethical approval and consent to participate

The study (07/03/2022-191) began with approval from the Gazi University Ethical Committee. In conformity with the Helsinki Declaration, all procedures were carried out.

Competing interests

None declared.

REFERENCES

- Bouty A, Ayers KL, Pask A, Heloury Y, Sinclair AH. The Genetic and Environmental Factors Underlying Hypospadias. *Sex Dev.* 2015;9(5):239-259.
- Blaschko SD, Cunha GR, Baskin LS. Molecular mechanisms of external genitalia development. *Differentiation.* 2012;84(3):261-268.
- van der Horst HJ, de Wall LL. Hypospadias, all there is to know. *Eur J Pediatr.* 2017;176(4):435-441.
- George M, Schneuer FJ, Jamieson SE, Holland AJ. Genetic and environmental factors in the aetiology of hypospadias. *Pediatr Surg Int.* 2015;31(6):519-527.
- Kalfa N, Gaspari L, Ollivier M, Philibert P, Bergoug-noux A, Paris F, et al. Molecular genetics of hypospa-dias and cryptorchidism recent developments. *Clin Genet.* 2019;95(1):122-131.
- Chen Z, Lei Y, Finnell RH, Ding Y, Su Z, Wang Y, et al. Whole-exome sequencing study of hypospadias. *iScience.* 2023;26(5):106663.
- Haid B, Pechriggl E, Nägele F, Dudas J, Webersinke G, Rammer M, et al. FGF8, FGF10 and FGF receptor 2 in foreskin of children with hypospadias: an analysis of immunohistochemical expression patterns and gene transcription. *J Pediatr Urol.* 2020;16(1):41.e1-e10.
- Pichler R, Djedovic G, Klocker H, Heidegger I, Strasak A, Loidl W, et al. Quantitative measurement of the androgen receptor in prepuces of boys with and without hypospadias. *BJU Int.* 2013;112(2):265-270.
- Qiao L, Rodriguez E Jr, Weiss DA, Ferretti M, Ris-bridger G, Cunha GR, et al. Expression of estrogen receptor alpha and beta is decreased in hypospadias. *J Urol.* 2012;187(4):1427-1433.
- Khanna S, Shankar Raman V, Badwal S, Vinu Bal-raam KV. Quantification of the Androgen and Estro-gen Receptors in the Penile Tissues of Hypospadias in Comparison with Normal Children. *Fetal Pediatr Pathol.* 2023;42(2):175-186.
- Kocaturk H, Özkaya F, Adanur S, Yapanoglu T, Ak-soy Y. Expression of androgen receptor and estrogen receptor-beta in foreskin tissue of hypospadiac and healthy boys. *Arch Esp Urol.* 2020;73(2):119-125.
- Nikolaev VV, Solontsov YN. [Epidemiology and theories of the origin of hypospadias]. *Urologiia.* 2018;(3):141-145.
- Marrocco G, Grammatico P, Vallasciani S, Gulia C, Zangari A, Marrocco F, et al. Environmental, paren-tal and gestational factors that influence the occur-rence of hypospadias in male patients. *J Pediatr Urol.* 2015;11(1):12-19.
- Zhou X, Zhang X, Zhou X, Abulimiti G, Wang Y, Zhang Q, et al. Identification of endocrine-disrupting chemicals targeting the genes and pathways of genital anomalies in males. *Ecotoxicol Environ Saf.* 2022; 247:114241.
- Cripps SM, Mattiske DM, Black JR, Risbridger GP, Govers LC, Phillips TR, et al. A loss of estrogen sig-naling in the aromatase deficient mouse penis results in mild hypospadias. *Differentiation.* 2019;109: 42-52.
- Do MT, Kim L, Im YJ, Hahn S, Park K. Effect of Preoperative Androgen Stimulation on Penile Size and Postoperative Complication Rate in Patients with Hypospadias: A Systematic Review and Meta-analysis. *World J Mens Health.* 2023; 41(3):558-574.
- Nagaraja MR, Gubbala SP, Delphine Silvia CRW, Amanchy R. Molecular diagnostics of disorders of sexual development: an Indian survey and sys-tems biology perspective. *Syst Biol Reprod Med.* 2019;65(2):105-120.
- Celayir A, Moralioglu S, Cetiner H, Kir G, Celayir S. Expression of androgen, estrogen, and progesterone hormone receptors in the penile tissues of children with different types of hypospadias. *North Clin Is-tanb.* 2018;6(2):110-116.
- Cunha GR, Risbridger G, Wang H, Place NJ, Grum-bach M, Cunha TJ, et al. Development of the external genitalia: perspectives from the spotted hyena (*Cro-cuta crocuta*). *Differentiation.* 2014;87(1-2):4-22.
- Joodi M, Amerizadeh F, Hassanian SM, Erfani M, Ghayour-Mobarhan M, Ferns GA, et al. The ge-netic factors contributing to hypospadias and their clinical utility in its diagnosis. *J Cell Physiol.* 2019; 234(5):5519-5523.
- Lorenzi MV, Long JE, Miki T, Aaronson SA. Expres-sion cloning, developmental expression and chro-mosomal localization of fibroblast growth factor-8. *Oncogene.* 1995;10(10):2051-2055.
- Gnanapragasam VJ, Robson CN, Neal DE, Leung HY. Regulation of FGF8 expression by the andro-gen receptor in human prostate cancer. *Oncogene.* 2002;21(33):5069-5080.
- Gredler ML, Seifert AW, Cohn MJ. Tissue-specific roles of FGFR-2 in development of the external geni-talia. *Development.* 2015;142(12):2203-2212.

