

DOUBLE ISOCHROMOSOME X, A RARE CYTOGENETIC VARIANT OF TURNER SYNDROME: A CASE REPORT AND A REVIEW OF THE LITERATURE

Zerrouki K.^{1,2}, Elidrissi Errahhali M.¹, Elidrissi Errahhali M.¹,
Babakhouya A.^{1,3}, Tajir M.^{1,2}

*Corresponding Author: Khawla Zerrouki; Address: Medical Genetics Laboratory, Mohammed VI University Hospital, BP 4806 Oujda University, 60049 Oujda, Morocco. Phone number: +212642540172; E-mail: khawlazerroukii@gmail.com

ABSTRACT

Turner Syndrome (TS) is a genetic disorder caused by total or partial loss of an X chromosome. The isochromosome X (i(X)) is a known variant of TS, however, double i(X) is a very rare variant, reported very few times in the literature. We report on a rare case of TS with double i(X). This is an 11-year-old female patient, addressed to the medical genetics consultation for short stature and facial features suggestive of TS. We performed a constitutional postnatal karyotype from a peripheral blood sample, with lymphocyte culture, and an R band analysis, performed on 70 metaphases. Metaphases analysis in our patient identified the presence of three cell populations: 45,X[22]/46,X,i(X)(q10)[30]/47,X,i(X)(q10),i(X)(q10)[18]. The first has total chromosome X monosomy, the second with a normal X chromosome and one isochromosome of the long arm of the other X chromosome and the third with a normal X chromosome and two isochromosomes of the long arm of the X chromosome. A control cell culture was performed from a second blood sample of the patient and confirmed the abnormality. This paper will discuss this case in comparison with other rare cases described, as well as the formation of the double isochromosome, based on the literature.

Keywords:

Double isochromosome, Mosaicism, Turner Syndrome, Rare case

INTRODUCTION

Turner Syndrome (TS) is a genetic disorder caused by total or partial loss of an X chromosome(1). Its first clinical description was in 1938 by Henry Turner and the chromosomal abnormality was found in 1956 by C.E Ford (2). This is the most common chromosomal abnormality in girls. It occurs in 1 in 2,500 live-born females (1,3). Phenotypic presentation is heterogeneous (4). A chromosomal analysis (karyotype) confirms the diagnosis and shows a total monosomy of the X chromosome (45,X) in about 50% of cases, or with other forms represented by mosaic formulas and structural anomalies of the X chromosome (deletions, ring, isochromosome). The isochromosome X (i(X)) is a known variant of TS, however, double i(X) is a very rare variant, reported very few times in the literature (5). We report on a rare case of TS with double i(X), and we review the literature regarding this rare anomaly.

PATIENTS AND METHODS

An 11-year-old female proband, the second of her siblings, non-consanguineous, her father (60 y/o) and mother (50 y/o). The pregnancy was well followed. The mother had a full term birth by a cesarean delivery due to the mother's narrow pelvis. There was no neonatal distress. The child's birth weight was 1500 g. Psychomotor development was normal except a delayed walk at the age of 3 years a half.

The clinical examination of the patient showed short stature, with a height of 115 cm (-3 SD) and a weight of 21 kg (-2 SD), palpebral slits slightly oriented up and out, low posterior hairline, broad chest with widely spaced nipples and a pectus excavatum. The patient is not yet pubescent (B1P1 according to tanner classification). These clinical findings have led us to suspect Turner Syndrome.

¹ Faculty of Medicine and Pharmacy, Mohammed Premier University, Oujda, Morocco.

² Medical Genetics Laboratory, Mohammed VI University Hospital, Oujda, Morocco.

³ Pediatrics department, Mother and Child Hospital, Mohammed VI University Hospital, Oujda, Morocco.

We performed a constitutional postnatal karyotype from a peripheral blood sample with a lymphocyte culture in our laboratory, using conventional RHG banding, and we analyzed 70 metaphases.

RESULTS

Metaphases analysis in our patient identified the presence of three cell populations:

- The first one has total chromosome X monosomy and represents 31% of the metaphases analyzed (Figure 1).
- The second, with a normal X chromosome, and one isochromosome of the long arm of the other X chromosome, found on 43% of the metaphases analyzed (Figure 1).
- The third one, with a normal X chromosome and two isochromosomes of the long arm of the X chromosome, found on 26% of the metaphases analyzed (Figure 1).

A control cell culture was performed from a second blood sample of the patient and confirmed the chromosomal abnormality.

DISCUSSION AND CONCLUSION

Isochromosome X is a structural chromosomal abnormality of the X chromosome that consists of two copies of either the p arm or the q arm, derived by centromere division (5). This results in an abnormal X chromosome whose two arms are genetically identical and causes TS. The most common isochromosome observed in the literature is the isochromosome for the long arm of the X chromosome (6). With or without mosaicism, its frequency was reported to be 15-18% in TS cases (7).

To our knowledge, the double i(X) is a very rare entity, described less than 10 times in the literature. The percentage of double i(X) ranges from 5% in Howell et al. to 36% in Melaragno et al. (8,9). The percentage of double i(X) is 26 % in our case (Table 1).

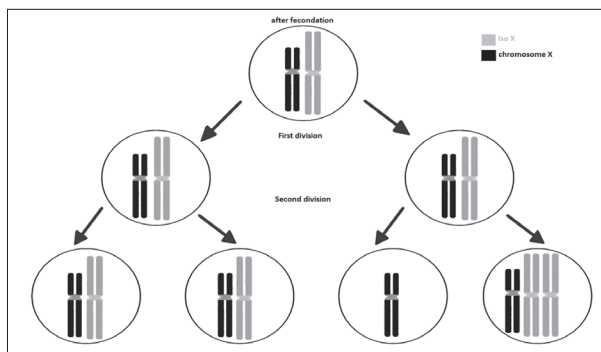


Figure 2. Diagram showing mitotic nondisjunction from gametes having a double isochromosome.

The absence of a normal population 46,XX indicates that the formation of i(X) occurred during meiosis by an isochromatid break and fusion of the daughter chromatids above the centromere or, by transverse division instead of longitudinal division of the centromere during cell division (10). We noticed that in all previously reported cases of TS with double i(X), the isochromosomes were dicentric. This suggests that mosaicism is a consequence of the instability of the dicentric chromosomes (9). We could pretend, in our case, that the i(X) is dicentric resulting in fusion of daughter chromatids. The segregation of the chromosome during cell division is normal due to one of the two centromeres of the dicentric isochromosome usually becoming non-functional (5). However, in this case, there is a failure of homologous chromosomes or sister chromatids to separate properly during cell division. There are three forms of nondisjunction: failure of sister chromatids to separate during mitosis (10,11). This latter mechanism is responsible for the presence of these three cell populations in our patient (Figure 2). Failure of a pair of homologous chromosomes to separate in meiosis I and failure of sister chromatids to separate during meiosis II.

The structural or numerical abnormality of X chromosome causes TS (4). The phenotypes of TS are very heterogeneous depending on the type of abnormality (12). The most common feature is short stature, which is found in 95% of patients, especially in patients with 46,X,i(Xq).




Figure 1. Results of R banding Karyotype: a) The first cell population: 45,X; b) The second cell population: 46,X,i(X)(q10); c) The third cell population: 47,X,i(X)(q10),i(X)(q10).

Table 1. Phenotype and Karyotype summary of cases with double Isochromosome X.

	Phenotype								Karyotype (percentage of cell)				
	Age	Psychomotor development	Stature	Spaced nipples	Low-set hairline	Others	Thyroid function	Tanner	45,X	46X.i(X)	47,X,i(X), i(X)	48,X, i(X), i(X), i(X)	49,X, i(X), i(X), i(X), i(X)
Our case	11	Normal	-3SD	+	Posterior	Up-slanting palpebral fissures	Euthyroids	B1P0	31	43	26	-	-
Melargno 1993(9)	25	NA	<-3 SD	NA	NA	NA	Hyperthyroidism	B3P4	44,5	21,6	33,3	0,6	-
	11	NA	<-3 SD	NA	Posterior	Cubitus valgus, pigmented nevi	NA	B1P1	53,3	25,3	19,3	-	-
Margaret et al 2010(19)	17	NA	<-3 SD	NA	NA	NA	NA	Poorly developed	4	88	8	-	-
Howell et al, 1976(8)	18	Normal	<-3 SD	NA	NA	NA	NA	Development after therapy	19	82	5	-	-
Palmer and Reichmann 1976(20)	NA	NA	NA	NA	NA	NA	NA	NA	50	48	2	-	-
									5	90	5	-	-
									18	78	2	2	-
Niebuhr et al. 1977(21)	10	Normal	<-3 SD	+	NA	Labia majora clitoris absent, cubitus valgus.	NA	NA	18	78	4	-	-
	16	NA	<-3 SD	-	+	NA	NA	B1	72	25	3	-	-
	8	NA	NA	NA	NA	NA	NA	Pubic hair	47	46	7	-	-
Lillian et al. 1978(22)	NA	NA	<-3 SD	-	+	Cubitus valgus	NA	NA	36	62	2	-	-
Huang et al. 2020(23)	30	Normal	-2 DS	NA	NA	NA	hypothyroidism	NA	1	49	1	-	49

NA: not available, SD: standard derivation, (B: Breast, P: Pubic hair: Tanner classification)

This can be explained by the haplo-insufficiency of the short stature homeobox gene (*SHOX*), that is in the pseudoautosomal region (PAR1) (refractory to X inactivation) in the short arm of X chromosome (13–16).

Ovarian dysgenesis, congenital lymphedema, pterygium colli, and some facial features are also described in TS (17). Some physical appearances of patients are generally related to bone abnormalities such as a short neck, cubitus valgus, and Madelung deformity. In our case, the proband has a short stature, some facial features, and delayed development of secondary sex characteristics, yet she has no heart disease, no bone abnormalities, thyroid function tests are normal and she does not complain from digestive symptoms. In general, the 46,X,i(Xq) and 45,XO karyotype show the same clinical manifestations of Turner's Syndrome (18). The other patients described with the 3 cells lines with double i(X) have also a phenotype suggesting TS.

Most often, Turner Syndrome is a sporadic event, and the risk of recurrence is not increased in subsequent

pregnancies (4). As we explained above, the formation of the iso X in our patient took place during meiosis, therefore a karyotype of the parents is not necessary.

The parents benefited from a genetic counseling consultation and the patient has regular medical follow-ups with the pediatricians to screen for other possible clinical manifestations and to establish hormonal treatment.

Consent for publication

Written informed consent for publication was obtained from the parents of the proband

List of abbreviations:

TS: Turner Syndrome
i(X): isochromosome X
SD: Standard deviation

Competing interests

The authors declare no conflict of interest.

REFERENCES

1. Silberbach M, Roos-Hesselink JW, Andersen NH, Braverman AC, Brown N, Collins RT, et al. Cardiovascular Health in Turner Syndrome: A Scientific Statement From the American Heart Association. Vol. 11, *Circulation*. Genomic and precision medicine. NLM (Medline); 2018: p. e000048.
2. Ford, K W Jones Wales Ce, Polani Pisa Mrcp Pe, C De Almeida Brazil J H Briggs Mb Lond Dj. A Sex-Chromosome Anomaly In a Case Of Gonadal Dysgenesis (Turner's Syndrome). *Lancet*. 1959; 711–713.
3. Gravholt CH, Andersen NH, Conway GS, Dekkers OM, Geffner ME, Klein KO, et al. Clinical practice guidelines for the care of girls and women with Turner Syndrome: Proceedings from the 2016 Cincinnati International Turner Syndrome Meeting. *Eur J Endocrinol*. 2017; 177(3): G1–70.
4. Jaime L. Fri'as, MD, Marsha L. Davenport M. American Academy Of Pediatrics Clinical Report Health Supervision for Children With Turner Syndrome [Internet]. 2003. Available from: www.aappublications.org/news
5. Ferguson-Smith MA. Isochromosome. In: Brenner's Encyclopedia of Genetics: Second Edition. Elsevier Inc. 2013; 138–138.
6. Gürsoy S, Erçal D. Turner Syndrome and Its Variants. *J Pediatr Res*. 2017; 171–5.
7. Wolff DJ, Van Dyke DL, Powell CM. Laboratory guideline for turner Syndrome. Vol. 12, *Genetics in Medicine*. Nature Publishing Group. 2010; 52–5.
8. Howell RT, Roberts SH, Beard RJ. Dicentric X isochromosomes in man. *J Med Genet*. 1976; 496–500.
9. Melaragno MI, Fakh LMA, Cernach MCSP, Maccagnan P. Isodicentric X Chromosome and Mosaicism: Report on Two Cases of 45, X / 46, X, idic (Xq) / 47, X, idic (Xq), idic (Xq) and Review of the Literature. *Am J Med Genet*. 1996 (359): 357–9.
10. Dimassi S, Tilla M, Sanlaville D. Anomalies chromosomiques. *J Pediatr Pueric* [Internet]. 2017;30(5–6):249–70. Available from: <http://dx.doi.org/10.1016/j.jp.2017.09.007>
11. David J. A, R.J. McKinlay G. *Chromosome Abnormalities and Genetic Counseling*. 5th ed. 2018. 971 p.
12. Villa N, Conconi D, Benussi DG, Tornese G, Crosti F, Sala E, et al. A complete duplication of X chromosome resulting in a trivalent isochromosome originated by centromere repositioning. *Mol Cytogenet*. 2017; 13: 10(1).
13. Ogata T. Turner Syndrome. *Encycl LIFE Sci*. 2001;(34 Pt 2):767–70.
14. Cabrol DS. Le Syndrome de Turner. *Ann Endocrinol (Paris)*. 2007; 1–13.
15. Cuesta Hernández M, Rueda Valencia ME, Pérez Rodríguez O, López De Lara D. Isocromosomas X: diagnóstico tardío de síndrome de Turner. *An Pediatr*. 2014;82(1):e131–4.
16. Sun Y, Luo Y, Qian Y, Chen M, Wang L, Li H, et al. Heterozygous Deletion of the SHOX Gene Enhancer in two Females With Clinical Heterogeneity Associating With Skewed XCI and Escaping XCI. *Front Genet*. 2019; 10:1–9.
17. Sybert VP, Mccauley E. Turner's Syndrome. *N Engl J Med*. 2004; 1227–38.
18. SATOSHI, YANACISA (Department of Pediatrics, Yamaguchi University School of Medicine, Ube J.), HIROSHI, YOKOYA (Department of Pediatrics, Yamaguchi University School of Medicine, Ube J. Symptoms of Turner's Syndrome and interstitial heterochromatin in i (Xq). *Clin Genet*. 1975; 299–303.
19. Margaret M., Tilak P. and Rajangam S. 45,X/47,X,i(X)(q10),i(X)(q10)/46,X,i(X)(q10) Isochromosome Xq in Mosaic Turner Syndrome *Int J Hum Genet*. 2010; 10(1-3): 77-80.
20. Palmer C. G. and Reichmann A. Chromosomal and Clinical Findings in 110 Females with Turner Syndrome. *Hum. Genet*. 1976; 35: 35-49 .
21. Niebuhr E. and Skovby F. Cytogenetic studies in seven individuals with an i(Xq) karyotype. *Hereditas*. 1977; 86: 121-128.
22. Hsu L.Y. F., Paciuc S., David K., Cristian S., Moloshok R. and Hirschhorn K. Number of C-bands of human isochromosome Xq and relation to 45,X mosaicism". *Journal of Medical Genetics*. 1978; 15: 222-226.
23. Huang, W. D. et al. "A Rare of Turner Syndrome with a Special Karyotype: A Case Report." *Clinical and Experimental Obstetrics and Gynecology*. 2020; 47(1): 129–31