

NOVEL *GPC3* GENE MUTATION IN SIMPSON-GOLABI-BEHMEL SYNDROME WITH ENDOCRINE ANOMALIES: A CASE REPORT

Bu W¹, Zhu M², Li S², Liu H³, Liu X^{2,*}

*Corresponding Author: Xiaomin Liu, M.D., Department of Neurology, the First Affiliated Hospital of Shandong First Medical University & Shandong Provincial Qianfoshan Hospital, 16766 Jingshi Road, Jinan 250014, Shandong, People's Republic of China. Tel: +86-531-89269012. Fax: +86-531-82967114. E-mail: bosucn@163.com

ABSTRACT

Simpson-Golabi-Behmel syndrome (SGBS) represents a rare X-linked recessive syndrome with prenatal and postnatal overgrowth, coarse facial features, congenital malformations, organomegaly and an increased risk of tumors. Mutations on the *GPC3* gene, encoding the glypican-3 protein, have previously been shown to cause the disease. In this report, a 12-year-old Chinese boy was hospitalized in our institution for some clinical features of SGBS. His serum endocrine evaluation showed hormone level abnormalities, including high prolactin, high testosterone, high thyroid-stimulating hormone (TSH) levels, and low estradiol levels. Whole exome sequencing (WES) was performed in the patient for mutation analysis and a novel hemizygous mutation, c.185delT, p.(Leu62Cysfs*22), on the *GPC3* gene, was identified. The mother was a heterozygous carrier. The SGBS patients might present with endocrine anomalies, which adds to the clinical heterogeneity of the disease. The novel *GPC3* mutation c.185delT expands the mutational spectrum of the *GPC3* gene.

Keywords: Endocrine anomalies; *GPC3* gene mutation; Simpson-Golabi-Behmel syndrome (SGBS).

INTRODUCTION

Simpson-Golabi-Behmel syndrome (SGBS) represents a rare X-linked recessive inherited overgrowth syndrome caused by *GPC3* gene mutations [1]. The phenotype is highly heterogeneous in patients, including prenatal and postnatal overgrowth, particular craniofacial characteristics, supernumerary nipples, organomegaly, heart or renal defects, gastrointestinal and genitourinary malformations, skeletal or hand abnormalities and tumor predisposition [2,3]. Here, we describe a novel *GPC3* gene mutation in a Chinese SGBS patient, who presented with endocrine anomalies.

CASE REPORT

A 12-year-old boy was hospitalized at our institution for developmental abnormalities. His family history revealed that he was born to non consanguineous parents [Figure 1(A)], and had macrosomia, with a birth weight 5.80 kg (>97th percentile) height 56.2 cm (>97th percentile) and head circumference 37.6 cm (>97th percentile). At the time of admission, his weight was 50.5 kg (75th-90th percentile), height 165 cm (>97th percentile) and head circumference 59.6 cm (>97th percentile). Physical examination revealed facial dysmorphism with coarse face, lip thickening, macroglossia with a midline furrow, pectus excavatum, supernumerary nipples, a broad nape and upper back, winged scapula, bilateral large hands and fingertips and nail dysplasia, predominately on the forefinger [Figure 1(B), 1(C), 1(D), 1(E) and (F)]. There was no intellectual disability and mental retardation.

Because of these developmental anomalies, he underwent serum endocrine hormone assessment (Table 1).

¹ Department of Neurology, Shandong Provincial Qianfoshan Hospital, Weifang Medical University, Jinan 250014, People's Republic of China

² Department of Neurology, the First Affiliated Hospital of Shandong First Medical University & Shandong Provincial Qianfoshan Hospital, Jinan 250014, People's Republic of China

³ Department of Neurology, Dingtao People's Hospital, Heze 274108, People's Republic of China

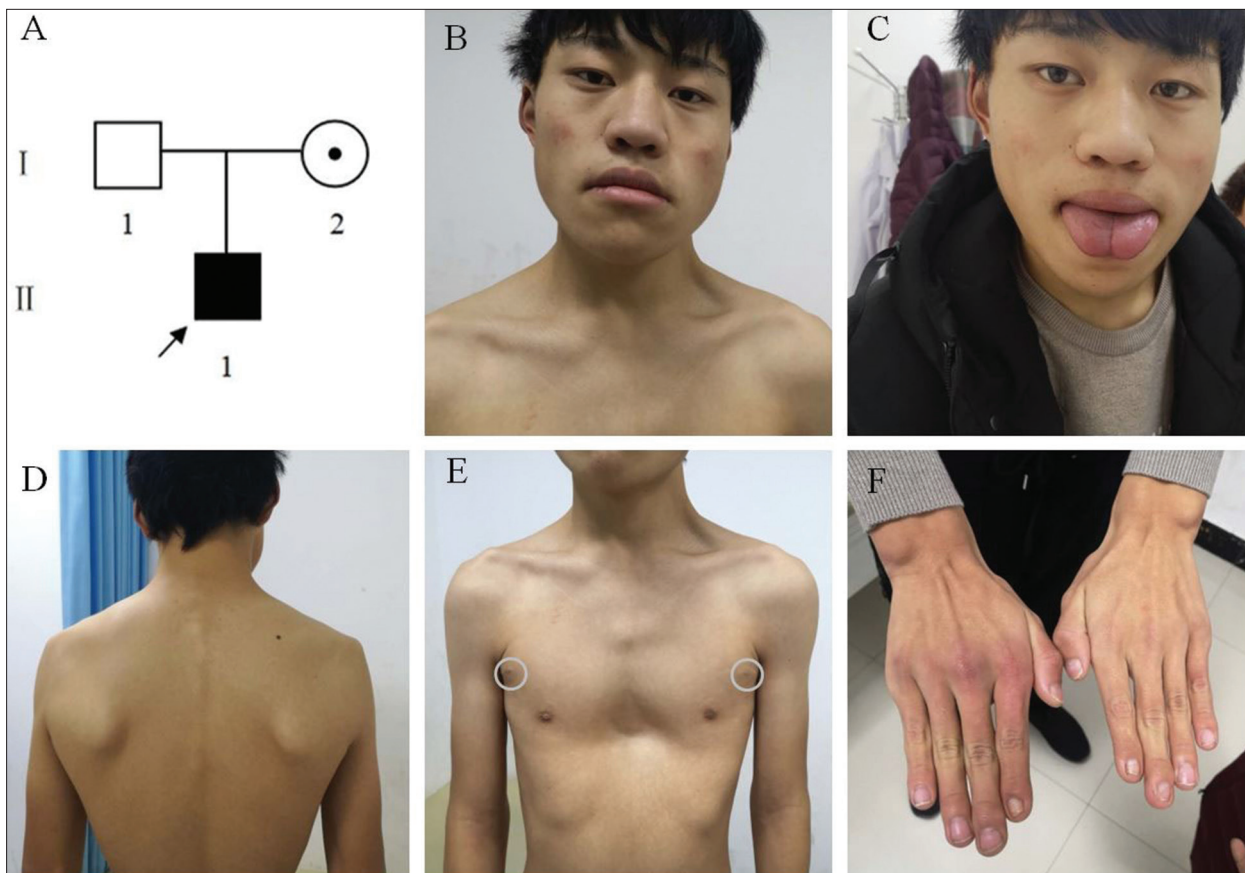


Figure 1. Pedigree and the patient. (A) Pedigree of the family with the Simpson-Golabi-Behmel syndrome. The proband is indicated by an arrow (B, C, D, E, F). Craniofacial features and trunk and hand abnormalities of the patient. Note the abnormal tongue shape. Circles indicate supernumerary nipples.

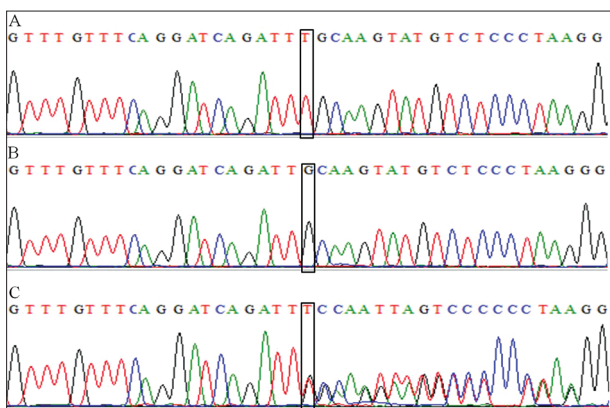


Figure 2. DNA sequencing results. (A) Wild-type *GPC3* gene sequence. (B) The hemizygous *GPC3* gene mutation, c.185delT, in the proband. (C) The heterozygous mutation carrier. Black frames indicate the c.185 nucleotide.

As for the hypothalamic-pituitary-gonadal axis, he had high prolactin (PRL), high testosterone and low estradiol levels. Meanwhile, follicle-stimulating hormone (FSH), luteinizing hormone (LH), and progesterone levels were

normal. High thyroid-stimulating hormone (TSH) levels were detected, whereas free triiodothyronine (FT3) and free thyroxine (FT4) levels were normal. The adrenal axis evaluation showed normal adrenocorticotropic hormone (ACTH) and random cortisol levels. Growth hormone (GH) levels were also normal. His 24-hour dynamic ECG revealed sinus rhythm and incomplete right bundle branch block. Echocardiography showed no signs of heart malformation and brain magnetic resonance imaging (MRI) revealed a normal-appearing pituitary.

DNA extraction was carried out from the peripheral blood samples collected from the proband, his mother and father after informed consent was obtained. The high-throughput sequencing technology was employed to assess the proband's whole exome. A specific *GPC3* gene mutation was verified by Sanger sequencing in all participants. By sequencing, a hemizygous mutation, c.185delT, p.(Leu62Cysfs*22), was detected in exon 2 of the *GPC3* gene in the proband. The mother was a heterozygous carrier [Figure 2(A), 2(B), 2(C)]. The mutation has not previously been reported. It was also not listed

Table 1. Endocrine evaluation of the patient with the *GPC3* c.185delT mutation.

Laboratory Test	Patient Value	Normal Range	Comment
Follicle-stimulating hormone	3.16 IU/L	1.50-12.40 IU/L (male)	normal
Luteinizing hormone	7.27 IU/L	1.70-8.60 IU/L (male)	normal
Prolactin	46.65 ng/mL	4.04-15.20 ng/mL	high
Testosterone	4.77 ng/mL	0.03-0.68 ng/mL	high
Estradiol	<5.00 ng/L	25.80-60.70 ng/L (male)	low
Progesterone	0.221 µg/L	0.200-1.400 µg/L (male)	normal
Thyroid-stimulating hormone	5.370 µIU/mL	0.270-4.200 µIU/mL (male)	high
Free triiodothyronine	4.54 pmol/L	3.50-7.70 pmol/L	normal
Free thyroxine	17.38 pmol/L	12.00-22.00 pmol/L	normal
Adrenocorticotrophic hormone	48.19 pg/mL	5.00-60.00 pg/mL	normal
Random cortisol	278.20 nmol/L (8:00 a.m.); 125.60 nmol/L (4:00 p.m.)	172.00-497.00 nmol/L (a.m.) 71.10-286.00 nmol/L (p.m.)	normal normal
Growth hormone	1.65 ng/mL	0.12-8.90 ng/mL	normal

in the major databases including the gnomAD, Clinvar, dbSNP, HGMD pro and LOVD. The parents of the patient provided written informed consent for publication of the case details and analyses. This study was approved by the Ethics Committee of Shandong First Medical University, Jinan, Shandong, People's Republic of China..

DISCUSSION

The current patient displayed some typical clinical features of SGBS, including macrosomia at birth, distinctive craniofacial features, supernumerary nipples, chest deformity, heart conduction defects and hand anomalies. In addition, the patient had hypothalamic-pituitary-gonadal axis dysfunction and thyroid impairment, which have rarely been described in SGBS. In 2008, Pénisson-Besnier *et al.* [4] described a 44-year-old male with SGBS, presenting with endocrine anomalies, including reduced LH and testosterone levels, while normal FSH, estradiol, TSH, and GH levels. In 2013, a patient with SGBS was reported with reduced morning random cortisol levels and an improper normal ACTH levels, low testosterone levels, and decreased sex hormone-binding globulin levels [5]. Recently, Zhang *et al.* [6] described a neonate of an SGBS patient, presenting with subclinical hypothyroidism, which is consistent with the patient in our study. These cases raise the question of putative endocrine problems in this disease. However, Cottreau *et al.* [2] described the clinical findings of 42 SGBS patients in their study and reviewed the data of 63 SGBS patients from the literature, all with a *GPC3* gene mutation. Although some patients had genitourinary malformations, among them 21 patients having cryptorchidism, and five patients had central nervous system malformations, none of the above endocrine anomalies have been reported. In addition, in

2019, Andrysiak-Mamos *et al.* [7] reported a 39-year-old male SGBS patient with suspected acromegaly. His MRI focusing on the pituitary gland revealed a series of abnormalities of median line structures, including a sellar-suprasellar cyst, persistent craniopharyngeal canal, a dysmorphic pituitary gland and a cyst of the septum pellucidum. However, his hormonal tests, including IGF1, GH, ACTH at 8:00 a.m., cortisol at 8:00 a.m., DHEAS, TSH, FT3, FT4, LH, FSH, testosterone and PRL, were not significant deviations. Thus, the association of endocrine anomalies and SGBS in our study may be merely coincidental.

A novel mutation, c.185delT, p.(Leu62Cysfs*22), was detected on the *GPC3* gene in the current family with SGBS. This mutation causes a Leu62Cys substitution. A concomitant frameshift maybe occur that introduces a new stop codon at 22 amino acid residues downstream to the new reading frame. This is predicted to lead to a polypeptide reduced by 498 amino acids compared with the wild type protein. Recently, Vuillaume *et al.* [3] reviewed 57 *GPC3* gene mutations reported in previous studies, and detected 29 novel mutations, most of which were large deletions (34.9%), frameshift (24.4%) and nonsense (16.3%) mutations. To date, at least 105 pathogenic mutations have been identified on the *GPC3* gene, including the one in our study and those listed in the professional version of the Human Gene Mutation Database. The *GPC3* gene encodes the 580 amino acid long glypican-3 protein, which is a heparan sulfate proteoglycan and cell surface oncofetal protein covalently binding to the exocytosomal surface of the cytoplasmic membrane. Glypicans can regulate multiple pathways, including the canonical Wnt/catenin, Hedgehog and fibroblast growth factor signaling, and have critical roles in cell proliferation and differentiation [8]. The majority of *GPC3* gene mutations are large

deletions or truncations, suggesting that loss-of-function is the mechanism responsible for SGBS [3].

Conclusions. We describe a novel *GPC3* gene mutation in a Chinese patient with SGBS who presented with endocrine anomalies. This report broadens the *GPC3* gene mutation spectrum, and provides novel insights into the clinical variability of SGBS. Further investigations are required to determine the genetic pathogenesis of SGBS.

Acknowledgments. We are deeply grateful to the family members for their participation in this study.

Declaration of Interest. The authors report no conflicts of interest. The authors alone are responsible for the content and writing of this article.

Funding. This study was supported by in part by the Natural Scientific Foundation of Shandong Province [ZR2013HQ016], and the Key Research and Development Project of Shandong Province [2015GGH318011].

REFERENCES

1. Pilia G, Hughes-Benzie RM, MacKenzie A, Bay-bayan P, Chen EY, Huber R, *et al.* Mutations in *GPC3*, a glypican gene, cause the Simpson-Golabi-Behmel overgrowth syndrome. *Nat Genet.* 1996; 12(3): 241-247.
2. Cottureau E, Mortemousque I, Moizard M-P, Bürglen L, Lacombe D, Gilbert-Dussardier B, *et al.* Phenotypic spectrum of Simpson-Golabi-Behmel syndrome in a series of 42 cases with a mutation in *GPC3* and review of the literature. *Am J Med Genet C Semin Med Genet.* 2013; 163C(2): 92-105.
3. Vuillaume M-L, Moizard M-P, Rossignol S, Cottureau E, Vonwill S, Alessandri J-L, *et al.* Mutation update for the *GPC3* gene involved in Simpson-Golabi-Behmel syndrome and review of the literature. *Hum Mutat.* 2018; 39(6): 790-805.
4. Péniisson-Besnier I, Lebouvier T, Moizard M-P, Ferré M, Barth M, Marc G, *et al.* Carotid artery dissection in an adult with the Simpson-Golabi- Behmel syndrome. *Am J Med Genet A.* 2008; 146A(4): 464-467.
5. Villarreal DD, Villarreal H, Paez AM, Peppas D, Lynch J, Roeder E, *et al.* A patient with a unique frameshift mutation in *GPC3*, causing Simpson-Golabi-Behmel syndrome, presenting with craniosynostosis, penoscrotal hypospadias, and a large prostatic utricle. *Am J Med Genet A.* 2013; 161A(12): 3121-3125.
6. Zhang J, Mu K, Xu H, Guo Y, Liu Z, Wang L, *et al.* Simpson-Golabi-Behmel syndrome type 1 with subclinical hypothyroidism: A case report. *Medicine (Baltimore).* 2019; 98(43). e17616.
7. Andrysiak-Mamos E, Sagan KP, Lietz-Kijak D, Kijak E, Kaźmierczak B, Pietrzyk A, *et al.* Simpson-Golabi-Behmel syndrome in a 39-year-old male patient with suspected acromegaly-A case study. *Am J Med Genet A.* 2019; 179(2): 322-328.
8. Ortiz MV, Roberts SS, Glade Bender J, Shukla N, Wexler LH. Immunotherapeutic targeting of *GPC3* in pediatric solid embryonal tumors. *Front Oncol.* 2019; 9: 108. eCollection 2019.